

## A 42-YEAR-OLD MAN WITH ACROMEGALY AND RELATED COMPLICATIONS: A CASE REPORT HIGHLIGHTING THE IMPORTANCE OF EARLY DIAGNOSIS OF A RARE CONDITION AND ITS FURTHER MANAGEMENT

Bilal Yasir Khan,<sup>1</sup> Alisaa K C,<sup>2</sup> Sumana Kundu,<sup>3</sup> Hazrat Ullah,<sup>4</sup> Lubna Mirza<sup>5</sup>

**How to cite:** : Khan BY, Alisaa KC, Kundu S, Ullah H, Mirza L. A 42-Year-Old man with Acromegaly and Related Complications: A Case Report Highlighting the Importance of Early Diagnosis of a Rare Condition and its Further Management. JAIMC 2023; 21(3): 223-226

Acromegaly is a rare and underdiagnosed disorder which is caused by a growth hormone (GH)-secreting pituitary adenoma<sup>1</sup>. Acromegaly has a prevalence of 60 cases per million and an incidence of 3-4 per million per year. The average age at presentation is about 44 years and both genders appear to be equally affected<sup>2</sup>. Persistent excess of both growth hormone and its target hormone insulin-like growth factor 1 (IGF-1) in Acromegaly results in a wide array of cardiovascular, respiratory, metabolic, musculoskeletal, neurological, and neoplastic comorbidities that might not be reversible with disease control.<sup>3</sup> Acromegaly is diagnosed with elevated serum insulin-like growth factor-1 and lack of growth hormone suppression after glucose administration<sup>4</sup>. Normalization of IGF-1 and growth hormone are the primary therapeutic aims; additional treatment goals include tumor shrinkage, managing complications, reducing excess morbidity, and improving quality of life. A multimodal approach with surgery, medical therapy, and (more rarely) radiation therapy is required to achieve these goals<sup>3</sup>. We present a case of Acromegaly with progressive and

insidious clinical manifestations demonstrating diagnostic and treatment challenges faced by treating physicians.

### CASE PRESENTATION

A 42-year-old man of American origin was referred to our endocrinology clinic by his primary care physician for further management of acromegaly. He said that he had gone through significant physical and emotional changes that started around 18 years ago in 2005 when he noticed changes in his hands and feet (see figure 1 and 2). They were getting progressively enlarged, coarse and puffy growing his shoe size from 10 to 13 in just 3 years. He developed deep voice and coarse facial features including enlarged nose and forehead, outwardly protruding jaws and widened gap in mandibular incisors. But these were all gradual and subtle changes that he only realized in retrospect. His puberty has been unremarkable with a normal growth spurt at the age of 15 attaining a height of 5'10". His height grew from 5'10" to 6' and his weight, from 130 lb to 200 lb during this time which got him into professional wrestling because of his overall appearance and huge body contour. He continued these activities for some years but then quitted because of pain in joints and muscles that started around 2019 at the age of 38 years.

1. Allama Iqbal Medical College, Jinnah Hospital Lahore, Pakistan

2. Alisaa K C

3. R. G. Kar Medical College, West Bengal, India

4. Khalifa Gul Nawaz Teaching Hospital, Bannu, Pakistan

5. Endocrinologist Norman Regional Hospital 3101 West Tecumseh Road Norman

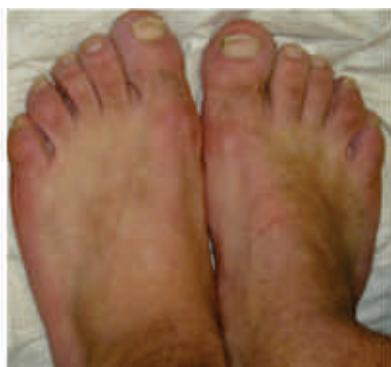### Correspondence:

Bilal Yasin Khan; MBBS, Allama Iqbal Medical College, Jinnah Hospital Lahore, Pakistan. Email: bilalyasin704@gmail.com

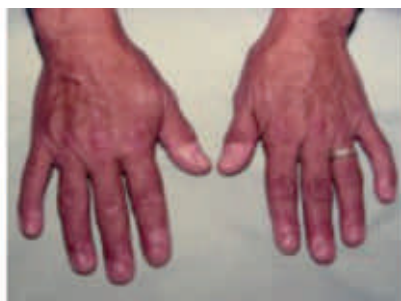Submission Date: 10-08-2023

1st Revision Date: 18-08-2023

Acceptance Date: 29-08-2023



**Figure 1:** Feet of the Patient (Taken with permission of patient.)



**Figure 2:** Hands of the Patient (Taken with permission of patient.)

His mood had become widely variable from being dynamic to apathetic and irritable. Additionally, he experienced insomnia resulting in daytime fatigue and headache.

In 2019, for the first time, he started experiencing intermittent and dull pain around his hips, shoulders, wrists, small joints of hands and his lower back which progressively became constant and moderately severe (4/10 on a pain rating scale) and also, better with oxycodone and worse with movements, compelling him to give up on wrestling. However, it was not until an MRI of his paranasal air sinuses was done for evaluation of chronic bacterial rhinosinusitis in 2019, the size of his pituitary gland (see figure 3) was found to be increased reported incidentally which was followed up by an IGF 1 testing (see table 1) and it was found to be elevated as well. Out of strong suspicion for acromegaly, he was referred to a neurosurgeon who diagnosed him with acromegaly.

**Table 1:** Levels of Growth Factor

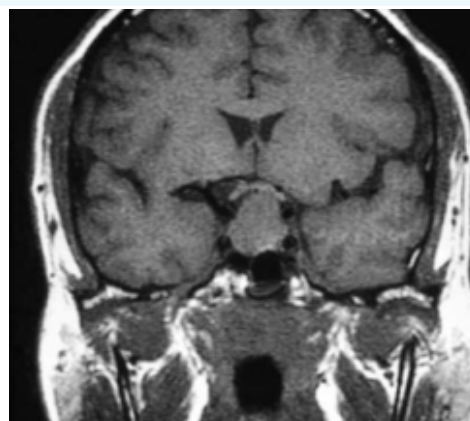
Insulin Like Growth Factor 1	Value	Reference Range
	1216 H	44-275 ng/mL

**Performing Lab:** Mayo Medical Laboratories. (06/08/2023). This test was developed and its performance characteristics determined by Mayo Clinic in a manner consistent with CLIA Requirements.

His Laboratory parameters showed –

**Table 2:** Laboratory parameters of the Patient

Test	Value	Reference Range
Hemoglobin	12.7	13.5-17.5g/dl
Hematocrit	39.1	41-53%
Prolactin	23.05	2.64-13.13ng/ml
Testosterone total	148.5	175-781 ng/dl
Triglyceride	152	<150 mg/dl
Cholesterol	222	<200 mg/dl
ACTH Mayo	78	7.2-63 pg/ml



**Figure 3:** MRI of brain showing size of pituitary gland

Next year, his condition worsened as he experienced constant fatigue throughout the day and persistent pain at his deltoid, lower back, thigh and calf muscles. He underwent transsphenoidal resection of the pituitary gland in May, 2020 followed by radiotherapy. Thereafter, he was referred to an endocrinologist who treated him with injections of octreotide, however, he admitted not being compliant with medication after four months onwards.

## DISCUSSION

Acromegaly, an acquired progressive somatic deformity mostly affecting the face, extremities and many other organs is linked to abundant Growth hormone (GH) production.

One of the most common causes of acromegaly is pituitary adenoma, which is typically a benign tumor.

As we could also see typical manifestations of

acromegaly in our patient like enlarged jaw, increased height, weight and enlarged hands and feet.

In addition to that, patients usually present with manifestations that include cardiovascular system (hypertension, ventricular hypertrophy, heart failure, arrhythmias), pulmonary (obstructive sleep apnea), neoplastic (colon polyps, colon cancer, differentiated thyroid cancer), endocrine and metabolic (insulin resistance and diabetes mellitus, oligomenorrhea), and musculoskeletal (vertebral deformities, osteoarthritis, carpal tunnel syndrome) comorbidities.<sup>8</sup>

The diagnosis of acromegaly is clinical and should be confirmed biochemically by the findings of increased serum GH concentrations which are not suppressed following an oral glucose load (oral glucose tolerance test, OGTT).

Basal GH and IGF-I measurements must be made when acromegaly is suspected, per a 2000 Consensus Declaration.<sup>9</sup> An oral 75 g glucose load (oral glucose tolerance test, or OGTT) must be carried out if the GH level is higher than 0.4 g/l (1.2 mIU/l). Acromegaly is confirmed if the lowest GH value during OGTT is more than 1 g/l (3 mIU/l).<sup>10</sup>

Our patient had increased GH and IGF1 on OGTT. Tumor excision, usually by the trans-sphenoidal route, is the most rapid and primary way of reducing GH and IGF-I concentrations in patients with acromegaly which was also performed in our patient.

First-generation somatostatin receptor ligands (octreotide acetate, octreotide long-acting release [LAR], lanreotide depot, oral octreotide) and a second generation SRL (pasireotide LAR) activate distinct subsets of somatostatin receptors (SSTRs), thereby inhibiting GH secretion while promoting apoptosis and exerting antiproliferative effects.<sup>11</sup>

As per Endocrine Society Clinical Practice Guideline, in a patient with significant disease (ie, with moderate-to-severe signs and symptoms of GH excess and without local mass effects), either a SRL or pegvisomant is used as the initial adjuvant medical therapy. SRL also acts as primary therapy in a patient who cannot be cured by surgery, has extensive cavernous sinus

invasion, does not have chiasmal compression, or is a poor surgical candidate.<sup>12</sup> Our patient had also taken octreotide for 4 months but wasn't compliant to it.

Another effective treatment modality is Radiation therapy, which is typically advised for those who are not in remission postoperatively and those who do not show a good response or tolerance to medical therapy.<sup>8</sup>

The primary treatment for our patient was trans-sphenoidal surgery. According to the Endocrine Society clinical practice recommendation, patients should receive SRL initially after surgery. In a patient who has not responded well to an SRL, the guideline recommends adding pegvisomant or cabergoline.<sup>13</sup> So, the optimum modality at this time is to provide SRL to our patient, monitor its effects and monitor the need of a second treatment modality.

## CONCLUSION

Early detection of Acromegaly is of paramount importance as it enables timely initiation of treatment and management which can help mitigate the irreversible bony changes, potential complications and improve patient's overall health outcomes.

## References

1. Vilar, Lucio, et al. "Acromegaly: clinical features at diagnosis." *Pituitary* 20 (2017): 22-32.
2. Holdaway, I. M., and C. Rajasoorya. "Epidemiology of acromegaly." *Pituitary* 2(1999): 29-41.
3. Fleseriu, Maria, et al. "Acromegaly: pathogenesis, diagnosis, and management." *The Lancet Diabetes & Endocrinology* (2022).
4. Ershadina, Nazanin, and Nicholas A. Tritos. "Diagnosis and treatment of acromegaly: an update." *Mayo Clinic Proceedings*. Vol. 97. No.2. Elsevier, 2022.
5. Giustina A, Veldhuis JD. Pathophysiology of the neuroregulation of growth hormone secretion in experimental animals and the human. *Endocr Rev*. 1998; 19(6): 717-797.
6. Cuevas-Ramos D, Carmichael JD, Cooper O, et al. A structural and functional acromegaly classification. *J Clin Endocrinol Metab*. 2015;100(1):122-131.
7. Lopes MBS. The 2017 World Health Organization classification of tumors of the pituitary gland: a summary. *Acta Neuropathol*. 2017;134(4):521-535.
8. Giustina A, Barkan A, Beckers A, et al. A consensus on the diagnosis and treatment of acromegaly comorbi-

- ditities: an update. *J Clin Endocrinol Metab.* 2020; 105(4): dgz096.
9. Giustina A, Barkan A, Casanueva FF, Cavagnini F, Frohman L, Ho K, Veldhuis J, Wass J, Von Werder K, Melmed S. Criteria for cure of acromegaly: a consensus statement. *J Clin Endocrinol Metab.* 2000; 85: 526–9. doi: 10.1210/jc.85.2.526.
10. Chanson P, Salenave S. Acromegaly. *Orphanet J Rare Dis.* 2008 Jun 25;3:17. doi: 11.1186/1750-1172-3-17. PMID: 18578866; PMCID: PMC2459162.
12. Gunther T, Tulipano G, Dournaud P, et al. International Union of Basic and Clinical Pharmacology. CV. Somatostatin receptors: structure, function, ligands, and new nomenclature. *Pharmacol Rev.* 2018; 70(4): 763-835.
13. Laurence Katznelson and others, Acromegaly: An Endocrine Society Clinical Practice Guideline, *The Journal of Clinical Endocrinology & Metabolism*, Volume 99, Issue 11, 1 November 2014, Pages 3933–3951, <https://doi.org/10.1210/jc.2014-2700>